

Intoeing in children

ORTHOPAEDIC FACT SHEET

Intoeing is when the feet turn inwards when walking. It is common in childhood and is usually outgrown. With intoeing, children might be prone to tripping, or look awkward when walking or running. There are three common causes of intoeing, which are described below.

1. Metatarsus adductus: the foot is turned inwards

The outside of the foot is normally straight. In metatarsus adductus, the foot curves inwards (**Figure 1**). Metatarsus adductus is thought to be related to the position of the baby in the mother's uterus. In most babies the foot is flexible, and improves without treatment by the age of two or three. Gentle exercise may help. Some children require shoe inserts or a short period of casting to help straighten their feet.

2. Internal tibial torsion: the lower leg

Internal tibial torsion is where the bone of the lower leg turns inwards between the knee and the ankle (**Figure 2**). It is very common in infancy and childhood, and usually corrects without treatment by the time the child is about eight years old. There are no specific exercises, braces or special shoes that can help.

3. Internal femoral torsion: the thigh bone

Internal femoral torsion is where the thigh bone turns inwards between the hip and the knee. This is normal in young children, and usually corrects without treatment by the time the child is about 10 years old. When sitting on the floor, children with this condition sometimes sit with their bottom between their heels. There is no evidence that this is harmful, but it might be wise to avoid it. There are no specific exercises, braces or special shoes that can help correct internal femoral torsion.

Intoeing is normal in children. However, consult your child's doctor if:

- intoeing affects only one leg
- intoeing is severe, and not improving with time
- intoeing is causing tripping in a school-age child that affects participation in activities
- the feet are stiff and not improving with time.

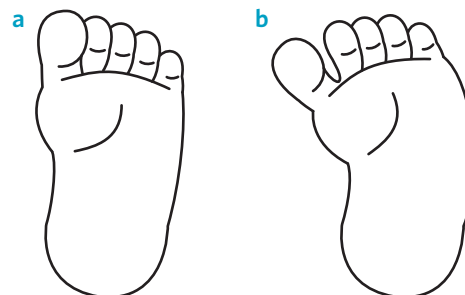


Figure 1. Normal foot (a)

Metatarsus adductus (b)

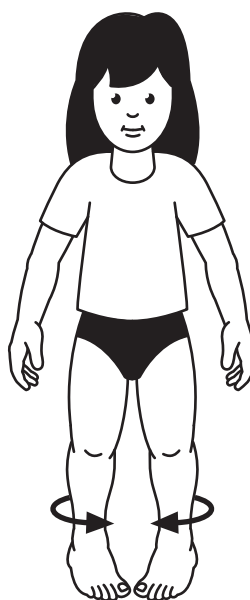


Figure 2. Internal tibial torsion — when the lower leg turns inwards between the knee and ankle

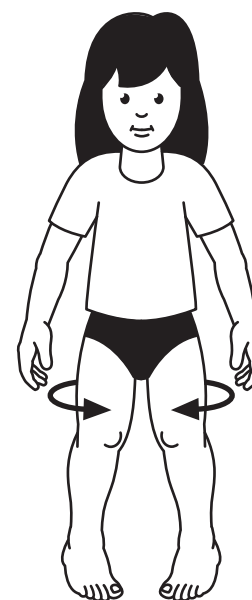


Figure 3. Internal femoral torsion — when the thigh bone turns inwards between the hip and the knee